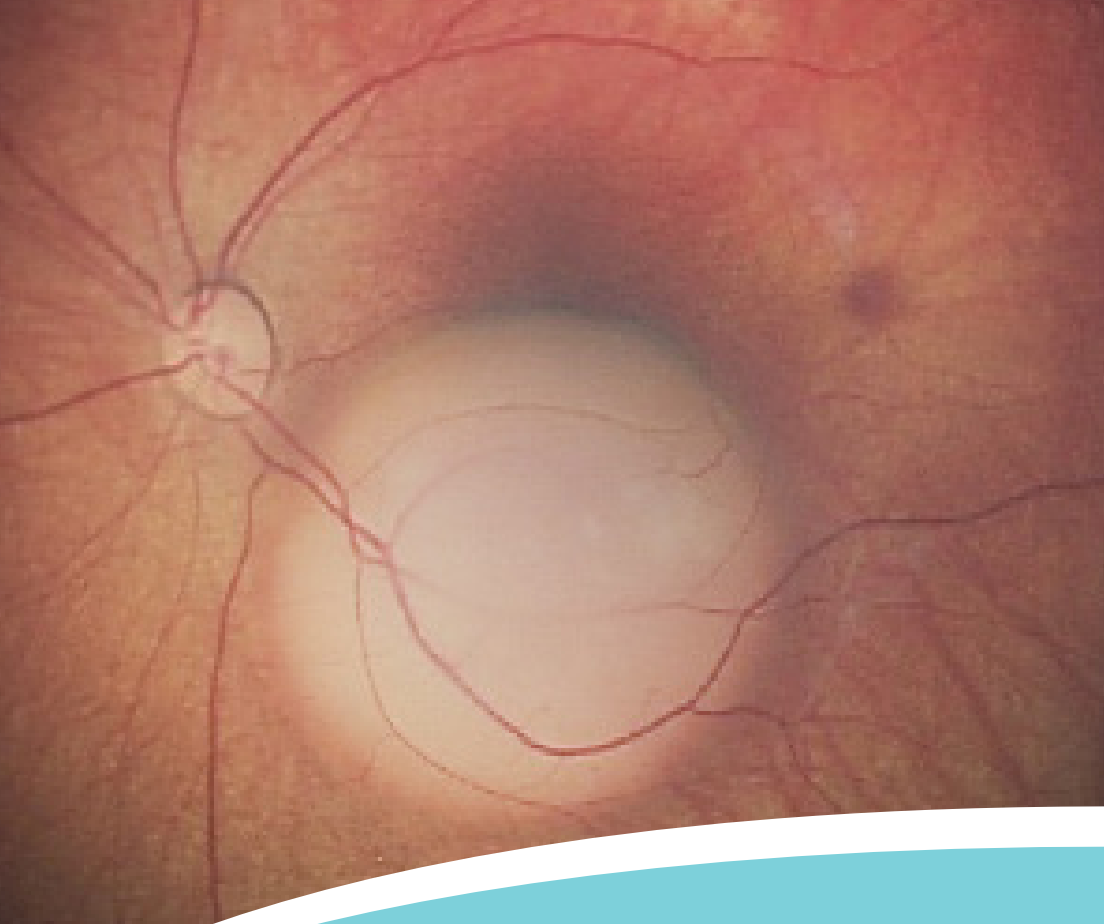


BASIC INFORMATION & TREATMENT PLANS OF Retinoblastoma

ALL INFORMATION PROVIDED BY:



**Ocular
Oncology
Service**

Wills Eye Hospital
Philadelphia, PA

840 WALNUT STREET SUITE 1440, PHILADELPHIA, PA 19107
WWW.FIGHTEYECANCER.COM | WWW.EYECANCERHEROES.COM | WWW.ETRF.ORG

Table of Contents

1. What is Retinoblastoma?	4
2. My Child Has Retinoblastoma	5
A. Examination	5
B. Diagnosis	5
3. Procedures & Treatment	6
A. Chemoreduction	7
B. Thermotherapy	7
C. Laser Photocoagulation	7
D. Cryotherapy	7
E. Plaque Radiotherapy	7
F. External Beam Radiotherapy	8
G. Intra-Arterial Chemotherapy	8
H. Intravitreal Chemotherapy	9
I. Enucleation	9
4. The Statistics	10
5. Ocular Prosthesis	12
6. Moving Forward	12
A. Future Appointments	12
B. Eye Protection	13
C. You Are Not Alone	13

What is Retinoblastoma?

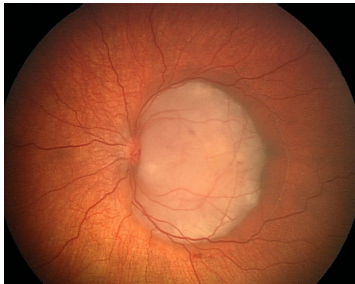
Retinoblastoma is the most common eye cancer in children.

It is a life-threatening cancer of the retina within the back of the eye. Retinoblastoma is discovered in babies between the ages of 6 and 24 months, although it can be found at earlier or later ages. Retinoblastoma occurs in approximately 1 in 15,000 live births, and it is estimated to affect approximately 250 to 300 children each year in the United States. Worldwide, about 5,000 children develop retinoblastoma each year.

Retinoblastoma occurs equally in boys and girls, and it is seen in all races. Retinoblastoma affects only one eye in about 70% of patients, and it affects both eyes in 30% of patients. In some instances, there is a family history of retinoblastoma in a parent or relative, but in the majority of cases there is no other member of the family affected with the tumor.

The cause of retinoblastoma is unknown. It has not been related to nutrition, smoking, drinking, or any maternal problem during pregnancy. It is not related to environmental toxins. It can develop in an otherwise healthy child despite a normal birth and early development.

Retinoblastoma develops from a single affected cell in the retina and it is invisible at its inception. Later, a small white nodule is noted



White tumor called Retinoblastoma

in the retina, but this is not visible to the parents, and it does not affect the child at this point. With time, the tumor grows into a larger white vascular tumor causing the child to lose vision painlessly. This can manifest in a drifting eye or an eye with a white or glassy-appearing pupil. At this point, the tumor is visible to the parents or grandparents and the

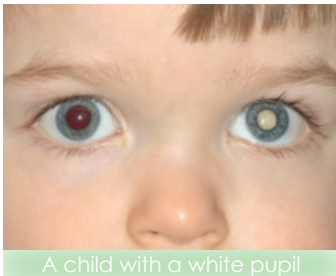child is typically taken to the doctor. Once a child is suspected of

My Child Has Retinoblastoma.

having retinoblastoma, a complete eye and systemic examination is required.

The ophthalmologist who suspects retinoblastoma typically refers the child relatively urgently (within one or two days or weeks) to a retinoblastoma expert. The retinoblastoma specialist evaluates the child's medical and family history, examines parents and family members, and then specifically focuses on the child's eye examination. The eyes are checked with the pupils dilated. The doctor wears a headlight, called an indirect ophthalmoscope, and she/he uses a focusing lens to see all of the details in the back of the eye. It is generally necessary to restrain the child to steady the head and body so that a reliable examination can be performed. Numbing eye drops are placed on the child's eyes for comfort. The child's eyelids are held open by a lid speculum, and soft cotton applicators are used to rotate the eyes gently to allow maximal visualization of the back of the eye. This is generally not painful to the child, but the child might cry.

The diagnosis of retinoblastoma depends primarily on findings seen on eye examination. On examination, retinoblastoma has a classic chalky-white appearance with prominent blood vessels. It is rarely necessary to biopsy the tumor for confirmation.



A child with a white pupil

To better assess the tumor, an examination with sedation of the child in the operating room, called an examination under anesthesia or EUA, is usually necessary. During the EUA, a complete eye examination with a detailed drawing of all tumors and related findings is performed. Other confirmatory tests like photography, ultrasonography, and

fluorescein angiography are performed. These tests assist in planning the treatment strategy for the child. Fluorescein angiography uses

an intravenous dye that discolors the child's urine to a green-yellow color for one day.

A pediatrician or a pediatric oncologist performs the pediatric examination. The systemic examination is based on how the eyes appear and what treatment is needed. It might include: Physical examination, CT and MRI of brain and orbits, blood tests, bone marrow analysis, hearing and kidney tests.

If on chemotherapy, the hearing and brain tests are important. The brain CT and MRI are usually performed twice yearly until age 5 years. These tests are done to evaluate for possible spread of the tumor as well as other related cancers.

If treatment is necessary, it is usually performed while the child is under anesthesia. Later, the doctors discuss the findings and treatment with the family. When the child recovers, the eyes might appear somewhat swollen and red for about 2 or 3 weeks. If the child is in the midst of treatment, appointments are about 1 month apart. If the child is stable, then appointments are usually 2 to 6 months apart. Lifelong, all children with retinoblastoma should have an eye examination once or twice yearly.

The goals of treatment of a child with retinoblastoma are threefold:

To save the child's life.

To save at least one eye.

To protect the vision.

There are several ways to treat retinoblastoma depending on the size, location, and multiplicity of tumors as well as the child's age, status of the opposite eye, and systemic condition. The treatment methods include: Chemoreduction, thermotherapy, laser photocoagulation, cryotherapy, plaque radiotherapy, external beam radiotherapy, and enucleation. These are often used in combination.

Chemoreduction is a method of using intravenous chemotherapy to reduce retinoblastoma to a small size so that the residual tumors can be eradicated with focal treatment methods like thermotherapy or cryotherapy. Chemoreduction is used in nearly all children with bilateral retinoblastoma and about 25% of children with unilateral retinoblastoma. This technique involves delivery of intravenous chemotherapy each month for 6 months. The delivery takes about 2 days of each month and is usually performed in Philadelphia at Children's Hospital of Philadelphia. Each chemotherapy session is coupled with an examination under anesthesia so that treatment of the tumor scars can be done the same day.

Thermotherapy is a laser method in which the residual tumor is heated for 5 to 15 minutes to a temperature that kills the cells. It is focal so that the surrounding tissue is unaffected. It typically leaves no external scars on the eye, but some children might show an irregular pupil after treatment.

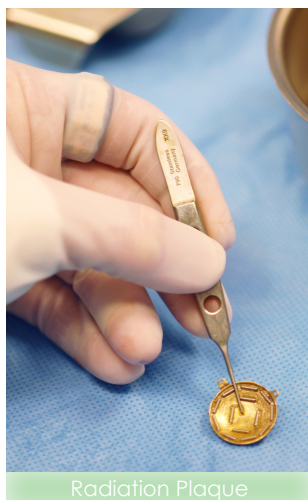Laser Photocoagulation is a method to treat a small retinoblastoma by closing the blood vessels to the tumor with heat. This causes no external scars on the eye but leaves a small scar on the retina.

Cryotherapy involves the use of a probe the size of a pencil placed on the eye to deliver a focal freeze for about 1 minute through the wall of the eye into a tumor inside the eye. Surrounding tissue is usually unaffected by this treatment. It typically leaves no external scars on the eye, but the eye is often swollen for 2 or 3 weeks.

Plaque Radiotherapy is a method of giving focal x-ray treatment to a small part of the eye by using a piece of metal, called a plaque. The plaque has implanted radiation, and it is sutured temporarily onto the eye directly over the retinoblastoma. The child stays in

Procedures and Treatment

the hospital for several days (usually 3 to 7 days) while the radiation plaque is in place. The radiation dose to the retinoblastoma is quite focal and limited to the eye itself with little radiation elsewhere to the body. After the correct dose is given, the plaque is removed in the operating room, and the child is discharged. Eye drops will be prescribed to be used 3 times a day for 3 weeks. The eye heals well over a few weeks. Long-term concerns include vision loss from cataract or retinal swelling. We have not seen radiation-related second cancers following plaque treatment.



Radiation Plaque

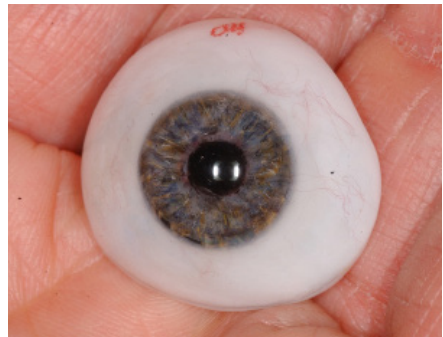External Beam Radiotherapy is a method of x-ray treatment to the entire eye by a radiation machine. This is available at only a few experienced centers worldwide. It takes about 4 weeks (Monday through Friday) in which small doses of radiation are given to achieve the final dose. External beam radiotherapy can cause the eye to feel irritated, dry, look red, and the patient might lose the eyelashes temporarily. This generally resolves, but the child is also at risk for long-term problems like vision loss from cataract or retinal swelling. There is also a risk for radiation-related second cancers, especially in children with bilateral retinoblastoma.

Intra-Arterial Chemotherapy (IAC) was introduced in Japan and modernized in the United States. It is a novel method of delivering chemotherapy directly into the eye. A fine catheter is passed into the femoral artery at the groin upwards through the heart and then into the ophthalmic artery of the eye. Chemotherapy is then injected into the eye under sterile conditions in the operating room. This technique limits systemic exposure and allows infusion of more potent chemotherapeutic agents. Intra-arterial chemotherapy can be given primarily in patients with unilateral retinoblastoma or secondarily when tumor recurs after chemoreduction or previous intra-arterial chemotherapy. It is given monthly for approximately 2-3 months. Although very effective, there is still a small risk of vision

loss, intra-operative stroke, bone marrow toxicity, and ocular vascular toxicity. Long-term effects on vision are also unknown at this point, but current studies have shown it maintains normal retinal anatomy after course completion.

Intravitreal Chemotherapy is a method of delivering chemotherapy into the vitreous cavity. Normally, the vitreous is the jelly portion of the eye that comprises the greatest volume of the eye and maintains its form. It is located in front of the retina and behind the lens. The vitreous is normally avascular, thus penetration of chemotherapy delivered through arteries is limited. The indications of intravitreal chemotherapy are limited to eyes with seeding of small retinoblastoma cells into the vitreous when other methods of chemotherapy fail to control proliferation of these seeds. It is a highly potent and targeted delivery of high dose chemotherapy directly into the vitreous through an intraocular injection. This limits penetration of drug into the systemic vasculature as well as periocular structures. It is given weekly or bi-weekly for approximately 5-6 times and is effective in almost all cases. This is always performed in the operating room with utmost caution to prevent seeding of retinoblastoma cells outside the eye through the needle tract. Cryotherapy is always performed during needle withdrawal to sterilize the needle tract. Possible complications are infection, bleeding, and retinal detachment; all of which are serious potentially blinding conditions but thankfully are rare occurring in less than 1% of all injections.

Enucleation is a method of removing the entire eyeball. The eyelids and muscles of the eye remain. This is used for eyes that have large tumors or eyes that have developed painful glaucoma. All other methods of treatment are considered before advising enucleation, but some patients have life-threatening large tumors that necessitate



Example of an ocular prosthesis

enucleation. Following enucleation, an implant is placed in the empty orbit and allowed to heal for 1 or 2 months. Then, an artificial eye (prosthesis) is made to match the remaining eye. The cosmetic appearance is generally outstanding with a natural appearance and comfortable fit as well as some movement of the eye. Protective lenses made of polycarbonate are advised to be worn at all times in the form of glasses during the day or goggles during activities or sports.

Recommended reading for vision in one eye is a book entitled:

A Singular View. The Art Of Seeing with One Eye by Frank Brady,
available online at www.amazon.com

Fortunately, most children with retinoblastoma survive and lead a good, long, and productive life. In the United States, nearly 98% of children survive. Not so in less advanced countries where about 50% of children die from tumor spread. Long-term ocular and pediatric examinations are advised for the child.

The prognosis of a child with retinoblastoma depends on several factors, most importantly the results of pathology. Children with retinoblastoma that has invaded into the optic nerve, choroid, sclera, orbit, or anterior chamber require chemotherapy as they are at greatest risk for metastasis (spread) and death. Those without invasion do not require chemotherapy.

There are several important aspects of the genetics of retinoblastoma. Retinoblastoma is classified into hereditary or nonhereditary types. Hereditary retinoblastoma patients are at increased risk for pineoblastoma, second cancers, and transmission of the genetic trait to their children.

Hereditary retinoblastoma includes:

- 100% of children with bilateral retinoblastoma
- 100% of children with familial retinoblastoma
- 10% of children with unilateral retinoblastoma

Nonhereditary retinoblastoma includes:
90% of children with unilateral retinoblastoma

The chance of having another child with
retinoblastoma depends on two factors:

- If the affected child has the tumor in one or both eyes.
- If there is another family member with retinoblastoma.

The following tables will give you an idea of the chances of having another child with retinoblastoma depending on these factors. Generally, if there is another family member with retinoblastoma, the parents have a higher chance of carrying the gene (trait) to pass on to future babies. If there is no family history of retinoblastoma and the child has the tumor in only one eye, then the chances of passing on the trait to future generations are much less.

Chances of having another child with retinoblastoma if there is no family history of retinoblastoma.			
# of Eyes Affected	Parents Affected	Child Affected	Normal Sibling
Two Eyes	6%	40%	1%
One Eye	1%	8%	1%

Table 1

Chances of having another child with retinoblastoma if there is a family history of retinoblastoma.			
# of Eyes Affected	Parents Affected	Child Affected	Normal Sibling
Two Eyes	40%	40%	7%
One Eye	40%	40%	7%

Table 2

The Statistics

Ocular Prosthesis

When an eye is removed due to enucleation, the surgeon places an implant into the socket that remains buried in the tissue for life. About 6 weeks after surgery when the tissue is healed without swelling, an ocular prosthesis (artificial plastic eye) is fitted by an ocularist (artist who specializes in making the artificial human eye) to cover the buried implant. The prosthesis is a removable device and resembles a thick contact lens. The prosthesis fits comfortably and provides a natural appearing eye that matches the opposite eye.

A prosthesis can remain in the socket for life, but it should generally be cleaned daily while bathing or showering by rinsing the surface using clean, warm water. A warm washcloth can be used to wipe off debris without removing the prosthesis. Occasionally, the prosthesis should be removed to clean off mucus or debris. Most parents remove a child's prosthesis at home for cleaning every 3 to 6 months. If the child is seen by an ocularist or an eye doctor, then it can be cleaned at their facility. Sometimes a prosthesis feels dry and teardrops are necessary for lubrication.

During the child's lifetime, the eye socket will grow, and the prosthesis may need to be reshaped or even completely replaced to fit the socket. This will be determined by the ophthalmologist or ocularist. In general, the ocularist should check the prosthesis annually.

Future Appointments

The child will require repeat examinations by the retinoblastoma specialist during the first 6 years of life. When the child is an infant, an examination under anesthesia (EUA) will be scheduled every 1 to 6 months depending on the severity of the tumors and the age of the child. When the child is about 5 years old and mature enough to sit steady for an examination without sedation, the examination will be done in our office. Before leaving the hospital after each visit, it is important to schedule the next appointment. If appointments are frequently missed, the child might be at a serious medical and visual threat.

Moving Forward

Following treatment and for the remainder of her/his life, any child with retinoblastoma should have an eye examination twice a year. Also, a qualified medical examination by a pediatrician, a pediatric oncologist, or primary care physician is advised lifelong.

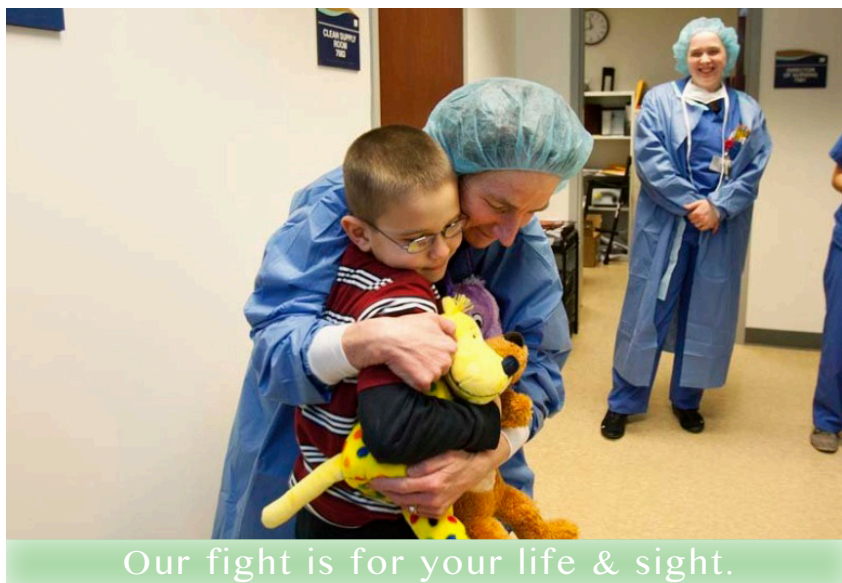Eye Protection

All children with retinoblastoma should wear protective polycarbonate glasses at all times and polycarbonate goggles during activities to shield the eyes from injury. These are available at most stores that sell eyeglasses as well as our office.

You Are Not Alone

You are not alone in this fight. If you are interested in reading the stories of other retinoblastoma patients please visit our website at:

www.EyeCancerHeroes.com



Our fight is for your life & sight.



840 WALNUT STREET SUITE 1440, PHILADELPHIA, PA 19107
WWW.FIGHTEYECANCER.COM | WWW.EYECANCERHEROES.COM | WWW.ETRF.ORG